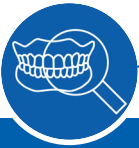

A Complex Two-Stage Implant Procedure for a Single Tooth Replacement With SPI®ELEMENT RC



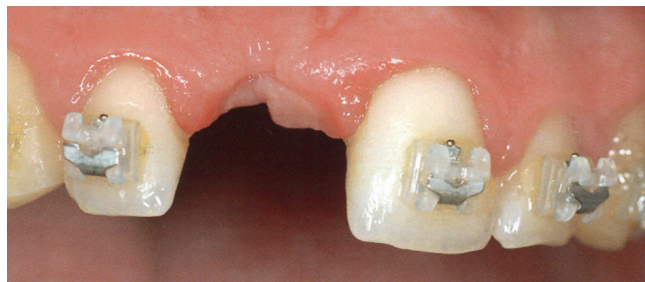
Dr. Ueli Grunder, Switzerland
 First published in: *Implants in the Esthetic Zone – A step by step treatment strategy*, Ueli Grunder, Quintessence Publishing



The Baseline Situation

Patient with missing central incisor

A 22-year-old male patient presented at the dental clinic after losing his right central incisor in an accident three years earlier. Following the completion of orthodontic treatment, he was prepared for dental implant therapy.



A very narrow ridge with vertical bone defects and scary indentations in the soft tissue were apparent

The Treatment Strategy



1. Insertion of a bone cylinder

Insertion of a bone cylinder harvested from the anterior nasal spine into the prepared bone bed. Stabilization with a central fixation screw

Coverage with a collagen bovine substitute material and a non-resorbable titanium-reinforced membrane followed by tension-free flap closure

2. Implant placement and horizontal ridge augmentation

Additional ridge augmentation procedure and implant placement (SPI®ELEMENT RC, PF 4.0) after 8 months of healing

3. Connective tissue grafting

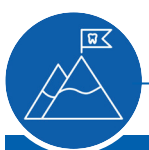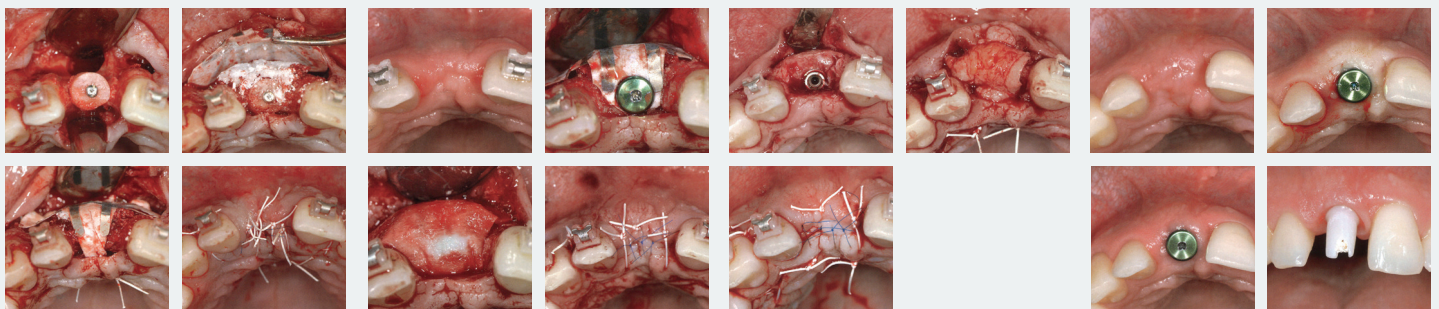
Tissue grafting from the palate combined with tight flap closure without vertical incision after 6 months of healing

4. Healing abutment and prosthetic restoration

Placement of a healing abutment to achieve relatively strong pressure on the soft tissue 4 weeks later

Impression taking and temporary restoration 4 weeks after stage-two surgery

Final restoration with an all-ceramic crown



The Outcome

A satisfactory final result was observed. No scarring was visible due to avoidance of vertical incisions in the anterior region. A retention wire was bonded for stabilizing the natural dentition to avoid gradual elongation. No displacement of adjacent teeth could be observed even 4 years after the treatment

